

Date	2018-07-02	Patient	Demo Patient	ID	456
Examination	ABI TBI PVR	Staff	Attending staff	Dept	Vascular Lab

## Examination Notes

52 year old male patient, healthy but complaining about leg pain. Could it be a vascular problem? Neither toe pressure, ABI or PVR are showing any signs of vascular disease. Cause of pain might be neurological.

## Medical History

SpO2 98

Patient supine Yes

Edematous skin

Left No

Right No

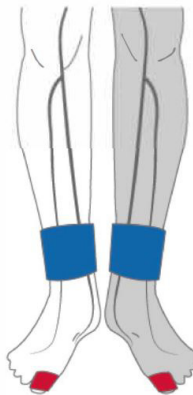
Diabetic No

Smoker Yes

Reference values	
ABI	0.91 - 1.40
TBI	> 0.70
Ankle pressure	> 70 mmHg
Toe pressure	> 50 mmHg

## Peripheral Pressure

Reference arm	
(RIGHT arm)	M
mmHg	122



RIGHT ankle PT	
(RIGHT arm)	M
mmHg	130
ABI	1.06

RIGHT ankle DP	
(RIGHT arm)	M
mmHg	134
ABI	1.09

LEFT ankle PT	
(RIGHT arm)	M
mmHg	111
ABI	0.90

LEFT ankle DP	
(RIGHT arm)	M
mmHg	136
ABI	1.11

RIGHT toe	
(RIGHT arm)	M
mmHg	141
TBI	1.15

LEFT toe	
(RIGHT arm)	M
mmHg	120
TBI	0.98

## Pulse Volume Recording - PVR

