

Date	2018-07-02	Patient	Demo Patient	ID	789
Examination	Segmental Pressure	Staff	Attending staff	Dept	Vascular Lab

## Examination Notes

60 year old male patient; smoker, no diabetes. Complaining about pain in right calf when walking. 55 mmHg between right thigh and right calf confirms PAD. Pressure drop between segments also confirmed by PVR.

## Medical History

SpO <sub>2</sub>	98
Patient supine	Yes
Edematous skin	
Left	No
Right	No

Diabetic	No
Smoker	Yes

Reference values	
ABI	0.91 - 1.40
TBI	> 0.70
Ankle pressure	> 70 mmHg
Toe pressure	> 50 mmHg
Between segments	< 20 mmHg

## Segmental Pressure

Reference arm	
(RIGHT arm) M	
mmHg	142

RIGHT thigh	
(RIGHT arm) M	
mmHg	160
Index	1.13

LEFT thigh	
(RIGHT arm) M	
mmHg	160
Index	1.13

RIGHT calf	
(RIGHT arm) M	
mmHg	105
Index	0.74

LEFT calf	
(RIGHT arm) M	
mmHg	155
Index	1.09

RIGHT ankle PT	
(RIGHT arm) M	
mmHg	98
ABI	0.69

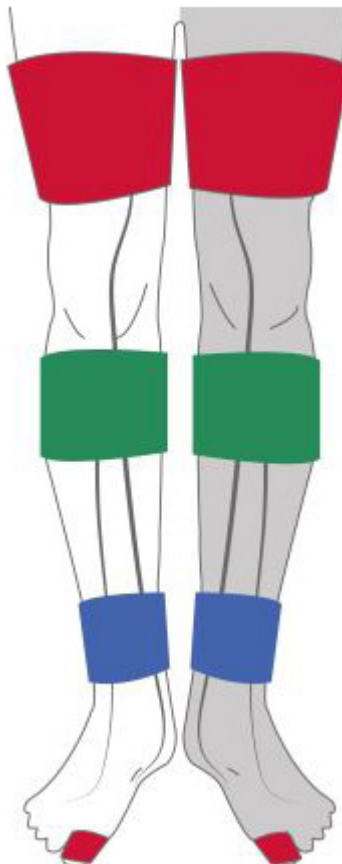
RIGHT ankle DP	
(RIGHT arm) M	
mmHg	102
ABI	0.72

LEFT ankle PT	
(RIGHT arm) M	
mmHg	151
ABI	1.06

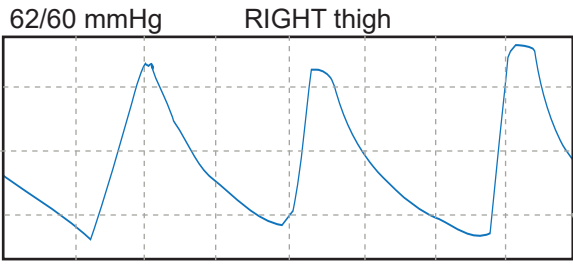
LEFT ankle DP	
(RIGHT arm) M	
mmHg	147
ABI	1.03

RIGHT toe	
(RIGHT arm) M	
mmHg	81
TBI	0.57

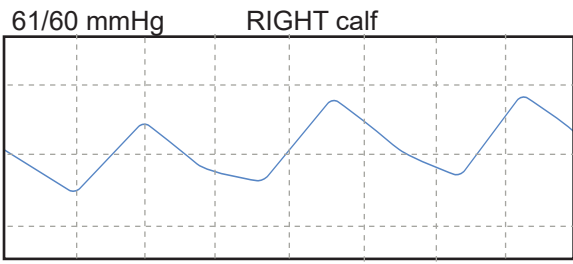
LEFT toe	
(RIGHT arm) M	
mmHg	127
TBI	0.89



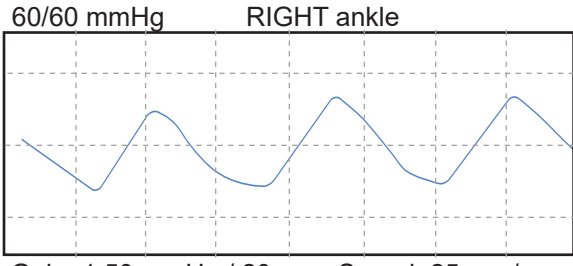
# Pulse Volume Recording - PVR



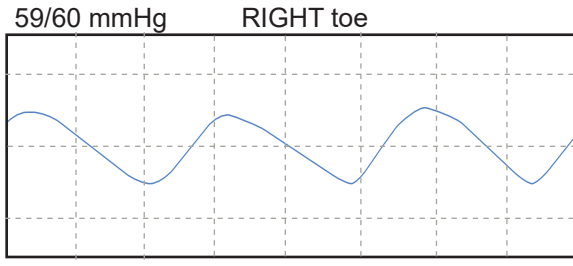
Gain: 1.50 mmHg / 20 mm Speed: 25 mm/sec



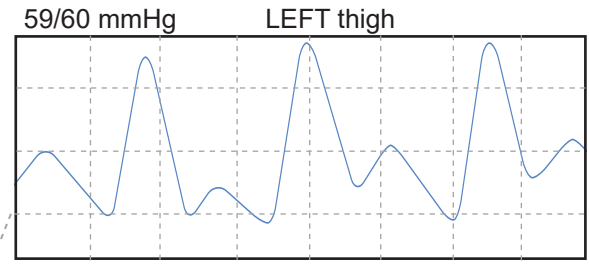
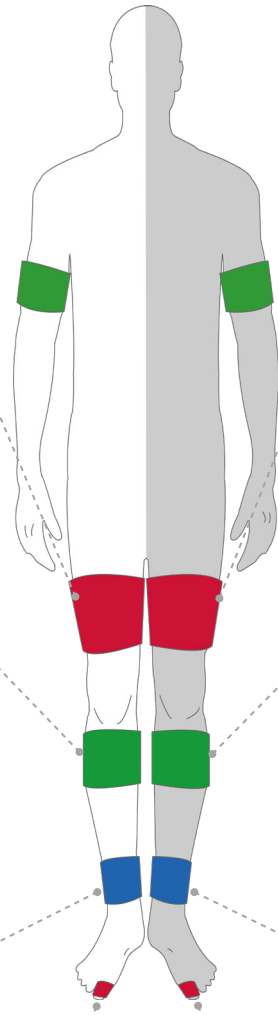
Gain: 1.50 mmHg / 20 mm Speed: 25 mm/sec



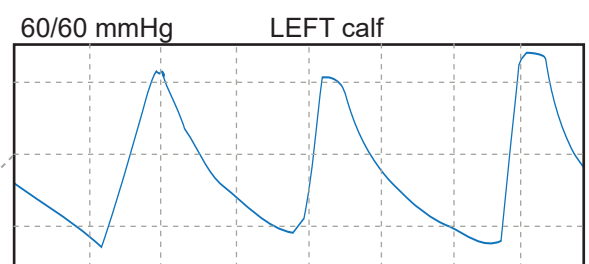
Gain: 1.50 mmHg / 20 mm Speed: 25 mm/sec



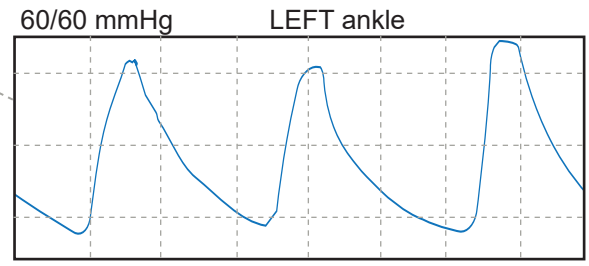
Gain: 0.50 mmHg / 20 mm Speed: 25 mm/sec



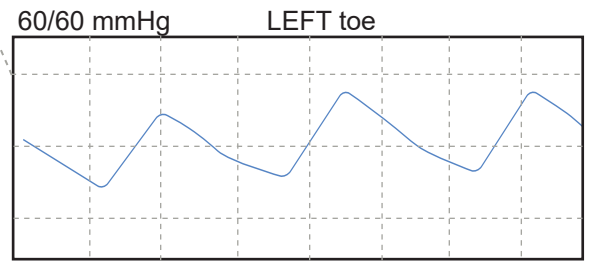
Gain: 1.50 mmHg / 20 mm Speed: 25 mm/sec



Gain: 1.50 mmHg / 20 mm Speed: 25 mm/sec



Gain: 1.50 mmHg / 20 mm Speed: 25 mm/sec



Gain: 0.50 mmHg / 20 mm Speed: 25 mm/sec